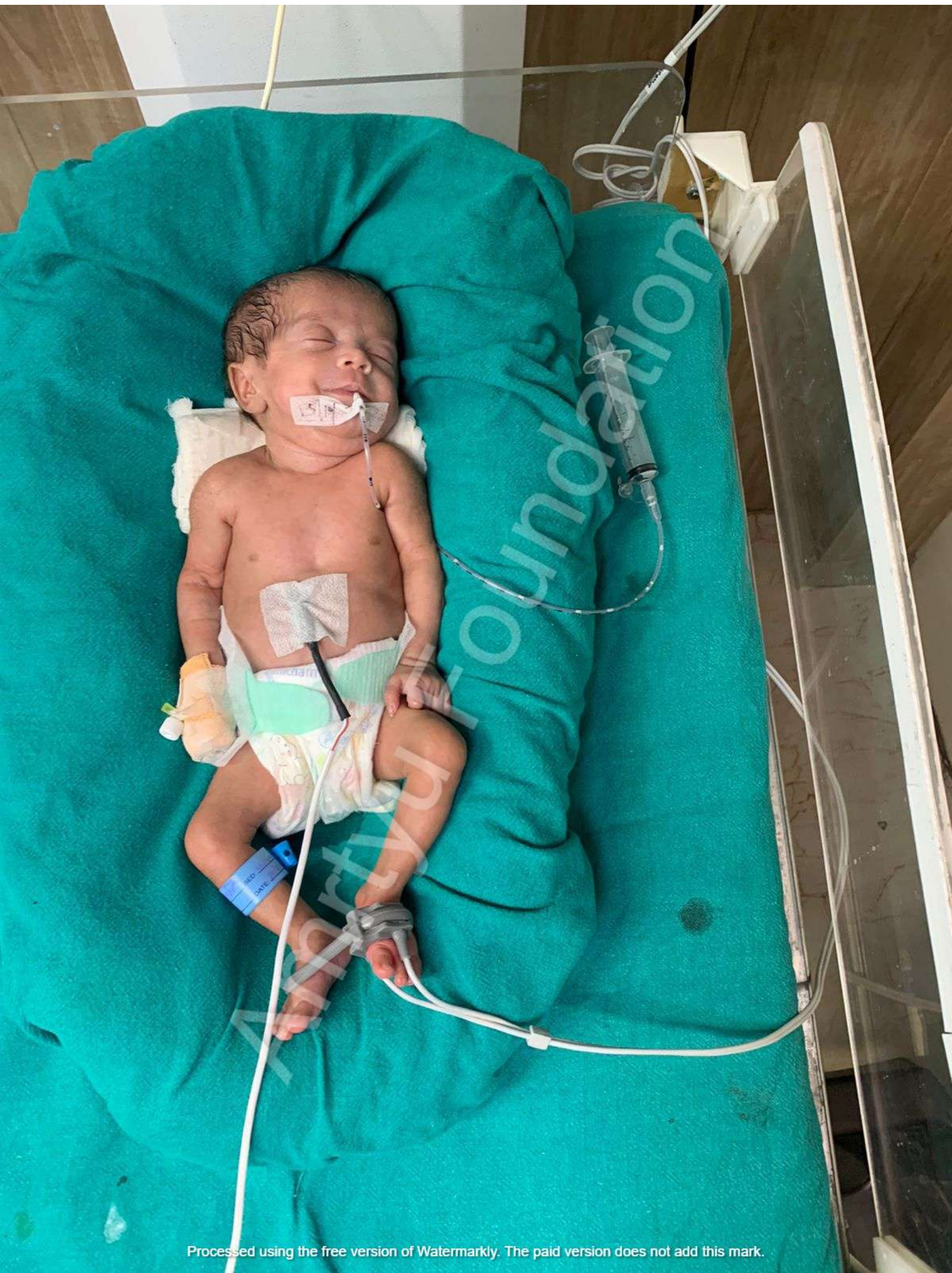





Silver Crest Hospital

4/9, Rattan Garden, New Colony Mor, Gurugram, Haryana-122001

Ph : 7303141112, E-mail : silvercresthospital@hotmail.com

Request Letter

To,

16-10-2024

Amrtyu Foundation.

Subject: Help the poor B/O Manju T2 (ID: 2467)


Respected Sir/Madam.

This is to certify that B/O Manju T2 (ID: 2467) is being treated at Silver Crest Hospital since 30-07-2024 as a case of extreme premature 28 weeks, 1.1kg. The expected stay is for another 1 month. Parents are very poor and are unable to bare the expenses.

Expected expenses would be: 1.5 lacs

Please help the poor baby financially and oblige them. That shall be of great help to the parents.

Yours Truly.


Dr. Mayank Singh

Silver Crest Hospital

Dr. Mayank Singh
M.B.B.S. M.D. Pediatrics
Fellowship in Neonatology
Regd. DMC 57733



Silver Crest Hospital

4/9, Rattan Garden, New Colony Mor, Gurugram, Haryana-122001
Ph : 7303141112, E-mail : silvercresthospital@hotmail.com

Name Dr. Manjeet D Age Sex F Wt Ht
ID 1146 Blood Group Date Of Admission 31/7/24
Consultant P.T Diet
Diagnosis

Doctor Progress notes

15/10/24
(no)

wt → 1.640 kg
HR - 140/min spo₂ - 92%
Tm | um | U4 - good BIA - 5/1
U1 < 20 mcell Tm | um | U4 - good
full on feeds. U7c 110 - 5/1
HR - 160 may decr

note: on feed 22ml / 2 no would
+ 1^o ml on each feed

15/11/24
(2)

- ac imping

easy all

RTA (2)
Pupose (2)
Mach
fan
on 8/2hr
Noun
RASV

Adw
eg
fry

It is tested for HIV-1 & II, HBV, HCV, Syphilis & Malaria (NAI & WNV)
and is carefully cross matched to make sure that it is compatible.

Brij Anand Path Lab

Fully Computerised Lab

JAS-ANZ



Acc No - 4420201U
www.jas-anz.org/regist

Date 12/10/2024
Name Adv. B/O MANJU T-2
Ref. By SILVER CREST HOSPITAL

Srl No. 12
Age 0 Yrs. 2 Mn. 15 Day
UHID 4240

Patient Id 24101212
Sex F

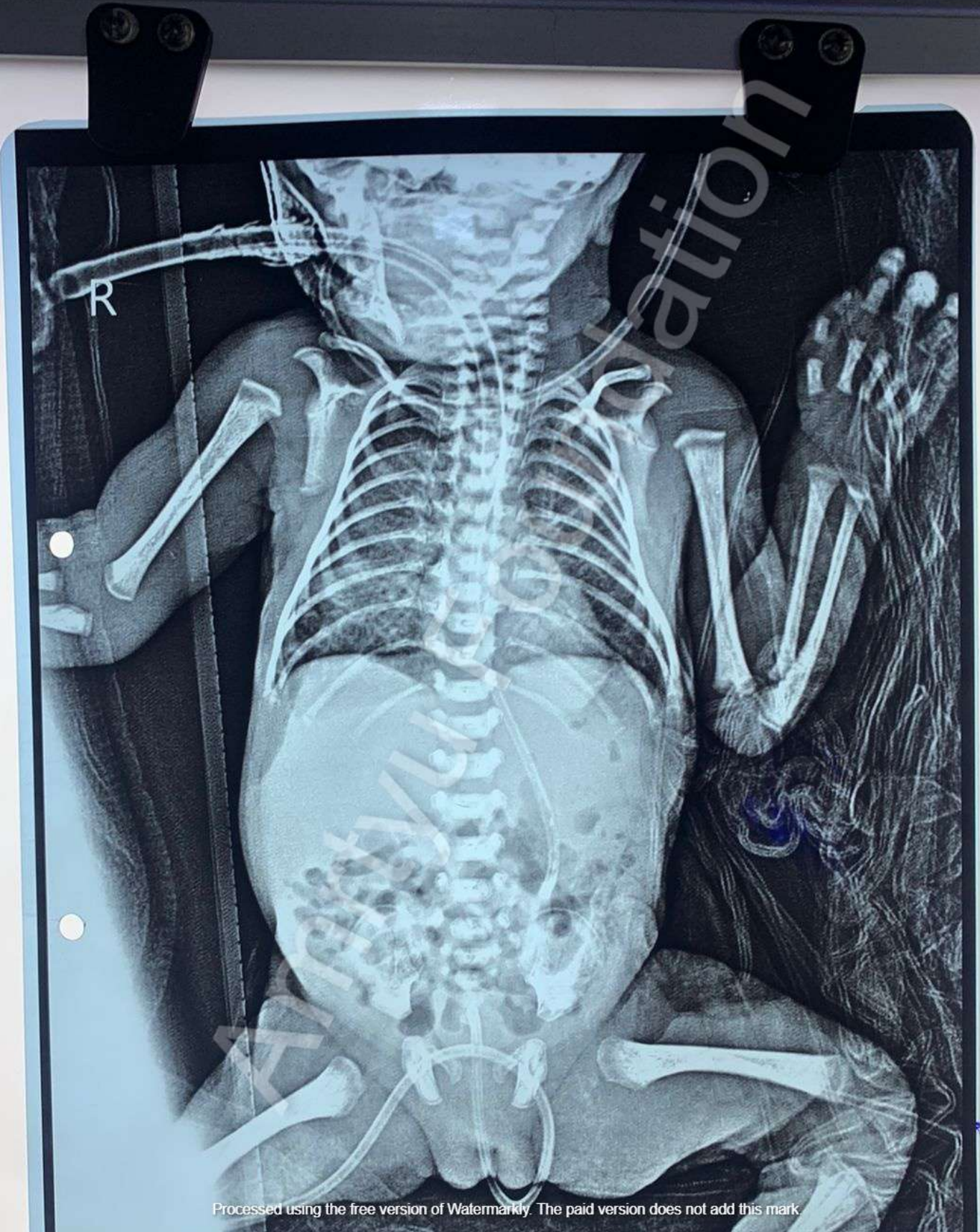
Test Name	Value	Unit	Normal Value
<u>COMPLETE HAEMOGRAM</u>			
HAEMOGLOBIN (Hb)	8.6	gm/dl	11.0 - 16.5
TOTAL LEUCOCYTE COUNT (TLC)	6,090	/cumm	6000 - 18000
DIFFERENTIAL LEUCOCYTE COUNT (DLC)			
NEUTROPHIL	48	%	40 - 75
LYMPHOCYTE	38	%	20 - 45
EOSINOPHIL	05	%	01 - 06
MONOCYTE	09	%	02 - 10
BASOPHIL	00	%	0 - 0
R B C COUNT	2.76	Millions/cmm	4.1 - 5.3
P.C.V / HAEMATOCRIT	24.7	%	35 - 45
M C V	89.6	fl.	80 - 100
M C H	31.2	Picogram	27.0 - 31.0
M C H C	34.8	gm/dl	33 - 37
PLATELET COUNT	2.67	Lakh/cmm	1.50 - 4.00

SEROLOGY

CRP (QUANTITATIVE) 3.34 mg/L (<6mg/L)

**** End Of Report ****

Dr. P.K. JAIN
M.D. PATHOLOGY
Reg.No. HR-HN-2142



Processed using the free version of Watermarkly. The paid version does not add this mark.



Silver Crest Hospital

4/9, Rattan Garden, New Colony Mor, Gurugram, Haryana-122001
Ph : 7303141112, E-mail : silvercresthospital@hotmail.com

11/10/2014

Bto Manju 2.

ROP procedure report

Diagnosis :

RIE zone 2 (Type 3 ROP with plus disease

LE zone 2 early stage 4A ROP with plus disease & pre-retinal hemorrhages

Procedure Done :

both prophylactic laser photocoagulation of avascular retina done.

LE manage laser post into the vitreous, traction temporarily given.

Drop orders :

lid Flu-T

lid Steroids

lid Refurb liquid

} 1 drop 8 hourly BUE
x 1wk

Review after 1wk

11/10/2014

19/10/24
10:15

19/10/24

Stable
Tolerating feed well
Vital signs
none weak

Continued Progress notes

By

16/10/24

(w)

WI - 1.86 kg
NR - 180 ml SpO₂ - 92%
Tm / um / ur - good

ell / cu well full on feeds

HR - 168 bpm dry

ell / p. P/A s/c

o/c: 00 feed 22 ml / r^o ml
+ 10 ml oil eat feed

16/10/24

(p)

Room cur full on feeds NR - 130 ml

W / u P/A s/c SpO₂ - 92%

Tm / um / ur good W / p. P/A

full on feed

at rest

nm / 58